The effect of calcium supplement —UNICAL—a calcium citrate combined with IAM on the ultrastructural alteration of mandibular condyle of weanling rats

Man Qin, Kenshi Maki, Wenyu Dai, Tomonobu Imamura, Mitsutaka Kimura and Guangxiang Shi

Reprinted from

PEDIATRIC DENTAL JOURNAL 10(1): 93–102, 2000

PEDIATRIC DENTAL JOURNAL 10(1): 93–102, 2000

The effect of calcium supplement —UNICAL—a calcium citrate combined with IAM on the ultrastructural alteration of mandibular condyle of weanling rats

Man Qin, Kenshi Maki, Wenyu Dai, Tomonobu Imamura, Mitsutaka Kimura and Guangxiang Shi*

Department of pediatric dentistry, Kyushu Dental College
2-6-1 Manazuru Kokurakita-ku, Kitakyushu 803-0844, JAPAN
* Department of Pediatric Dentistry, School of Stomatology, Beijing Medical University
38 Baishiqiao Road, Haidian Distinct, Beijing 100081, CHINA

Abstract In order to determine whether the calcium citrate combined with IAM (increased absorption materials), a kind of oral calcium supplement, made from sea urchin shell, called UNICAL®, had any beneficial effect on the bone debilitation, we examined the mandibular condyles of weanling Wistar's male rats by using scanning electron microscope (SEM) and transmission electron microscope (TEM). The SEM investigation demonstrated that the images of UNICAL® diet in the low calcium experiment rats were similar to that of the control group rats either in the mineralized hypertrophic cartilage or in the ossification areas. In the standard diet experiment rats of the low calcium group, the interstitium among condrocytic lacunae were wide, and the calcospherites sparse within a condrocytic, lacuna in the mineralized hypertrophic cartilage; and the some of collagen fibrils arranged to fibrillar bundles, and others crossed to network in ossification area bone matrix. In the calcium deficient experiment rats, the distinct network of collagen fibers connected the calcospherites with the condrocytic lacuna in the mineralized hypertrophic, cartilage; and the bone resorption areas were indicated in ossification areas. The TEM investigation showed that the images of UNICAL® diet in the low calcium experiment rats were similar to that of the control group rats except for the collagen fibrils surrounding active osteoblasts irregular somewhat. In the pair-fed standard diet experiment rats of the low calcium group, the 'young' osteocytes were commonly seen, and the collagen fibrils surrounding 'young' osteocytes were found to be irregular. The active osteoclasts, which had numerous mitochondria and lysosomes, and clear functional ruffled border, were often seen in UNICAL® diet experiment rats of calcium deficient group. These results suggested that the calcium citrate combined with IAM had relatively positive effect on the bone debilitation to a certain extent in growth period rats.

Key words
Bone debilitation,
Calcium citrate combined with IAM,
Mandibular condyle,
Scanning electron microscopy,
Transmission electron microscopy

Introduction

The determinants of bone growth and development include genetic, nutritional, weight loading (exercise) and environmental factors. Approximately 20–30% of bone structure can be influenced by postnatal factors, another 60–80% of that can be explained by genetic variations. Nutritional factors, especially calcium, are potentially most amenable to therapeutic manipulation[1-3].

Adequate calcium intake benefits bone at any

Received on October 30, 1999
Accepted on January 15, 2000

age. However, dietary calcium need vary at different ages. In fact, age exerts a major influence on the nutritional needs for bone health. Age influences the nutrient requirements for bone health by influencing: the growth and development of bone; the deposition of minerals leading to peak bone mass; the rate of bone loss; the levels of hormones which influence bone; the resorption and retention of nutrients for optimal bone health, physical activity, food intake, and the level of sun exposure[4]. Retrospective studies in adults suggest that calcium intake in childhood is associated with high risk of later osteoporosis and fracture[5,6]. Inadequate intake of calcium in weanling period is thought to take a sensitive effect on the bone growth and development. It is possible to induce unrecoverable damage on the bone mineral formation.

In addition, it attracts more and more dentists' attention to the influences of systemic bone debilitation on dental field, for instances, on the bone reparation after periapical abscess or periapical granuloma[7,8]; reorganization of periodontitis[9,10]; prognosis of implant[11]. This investigation was undertaken to determine the effect of calcium supplement, the calcium citrate made from sea shell combined with IAM, called UNICAL®, on the ultrastructural alteration of mandibular condyle of weanling rats.

Materials and methods

Animals and treatments

Forty Wistar's male weanling rats aging three-week-old, weighing roughly 40 g, maintained by Seiwa Experimental Animal Research Institute, were housed in small cages individually under similar conditions. All of the rat's food was made by Oriental Yeast Co. Ltd., Tokyo, Japan. In the control group, rats were fed on standard diet, containing 0.449% calcium, 0.608% phosphorus and 1000IU vitamin D_3 per 100 g, with tap water for six weeks. In the calcium deficient experiment group, rats were fed on no calcium component diet with distill water at first three weeks, then they were fed on the UNICAL® diet, which was a calcium citrate combined with IAM (increased absorption materials) made from sea shell, at later three weeks. In the low calcium experiment group, rats were fed on low calcium diet (calcium component is 30% of standard diet) with tap water at first three weeks, then they were allocated into two treatment groups and pair-fed on standard diet or UNICAL® diet with tap water at later three weeks.

After being fed six weeks, these rats were perfused through the left ventricle with a fixative mixture of 4% paraformaldhyde and 2% glutaraldehyde in 0.05 M sodium cacodylate buffer (pH7.4) under 4°C, while anesthetized with 1% sodium pentobarbital. Then the mandibular condyles were dissected out of all the rats, and divided into two parts symmetrically, later treated for the observations of scanning electron microscope and transmission electron microscope respectively.

The study was approved by the committee for the use of laboratory animals of Kyushu Dental College, Japan.

Sample preparation for scanning electron microscopy

The samples were fixed with 2.5% glutaraldehyde for one hour after being cleaned with 10% sodium hypochlorite solution by super sonic wave to get rid of adhesion. They were rinsed by buffered phosphate acid (pH7.2) before entering post-fixation. The post-fixation was performed in 1% osmic acid buffer solution (pH7.2) under 4°C for two hours. After fixation, these samples were dehydrated through a graded ethanol series, and treated with 2-methyl-α-propanol, then dried in *t*-butyl alcohol by freeze-drying method (ID-2, Japanese Electric Co., Ltd.). The cracked surfaces were sputter coated with aurum, later observed under a scanning electron microscope (JSM T-300, Japanese Electric Co., Ltd.).

Sample preparation for transmission electron microscopy

The samples were prefixed with the fixative under 4°C for one hour, while they were treated 5 sec-on–10 sec-off microwave irradiation for two minutes, then rinsed with 0.05 M sodium cacodylate buffer solution (pH7.4) before decalcification. The decalcification was performed in 5% EDTA-2Na solution for five days while being treated 5 sec-on–10 sec-off microwave irradiation for 2 min. per 12 h. The samples were rinsed with 0.05 M sodium cacodylate buffer solution (pH7.4) again. The postfixation was done with 1% osmic acid buffer solution (pH7.4) for two hours, then dehydration through a graded ethanol series, diaphanization in propylene oxide, finally embedding in epoxy resin. Semi thin sections were cut at 0.35 μm thickness, stained with toluidine blue,

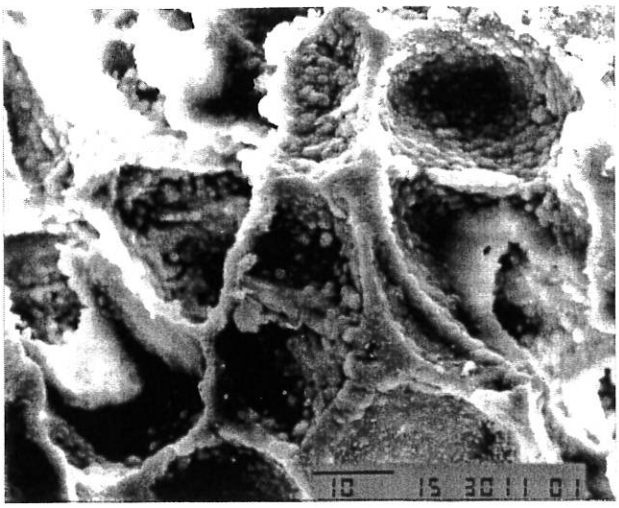

Fig. 1 SEM image of mineralized hypertrophic cartilage along the ossification front in UNICAL® diet experiment rats of the low calcium group. There are abundant calcospherites in condrocytic lacuna, and the slender collagen fibrils appeared among the calcospherites. Bar: 10 μm

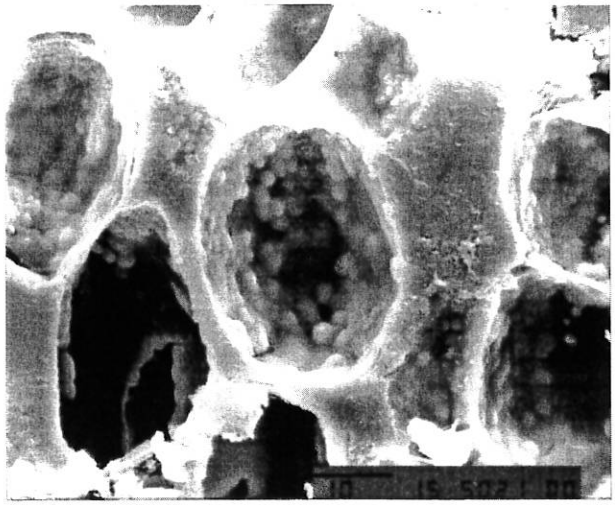

Fig. 2 SEM image of mineralized hypertrophic cartilage along the ossification front in pair-fed standard diet experiment rats of the low calcium group. The interstitium among condrocytic lacunae are wide, and the calcospherites sparse in condrocytic lacuna. The slender collagen fibrils appear among the calcospherites clearly. Bar: 10 μm

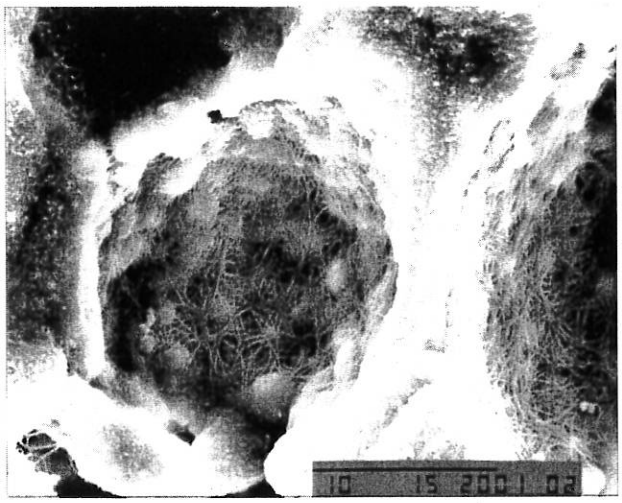

Fig. 3 SEM image of mineralized hypertrophic cartilage along the ossification front in UNICAL® diet experiment rats of the calcium deficient group. There is the distinct network of collagen fibrils connecting the calcospherites within condrocytic lacuna. Bar: 10 μm

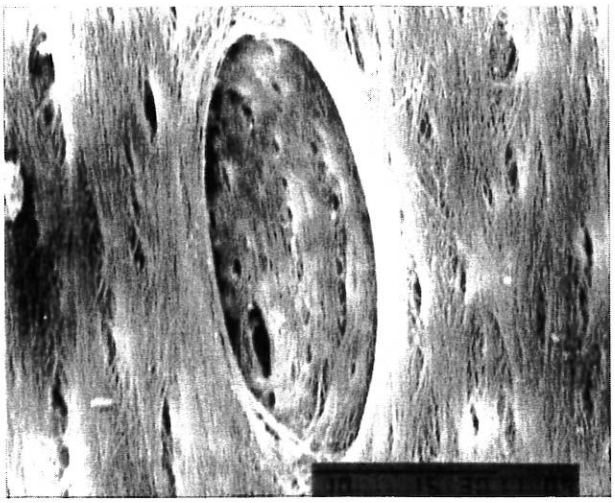

Fig. 4 SEM image of ossification area in the control group. The mature osteocyte with regular outline is shown. There are a lot of bone canaliculi opened their mouths at the wall of the osteocyte lacunae. The bone matrix consists of densely arranged collagen fibrils and contains a large number of closely packed collagen fibrillar bundles. Bar: 10 μm

and examined using light microscope to chose the target areas which would be observed in transmission electron microscope. The ultrathin serial sections were cut at 70–100 nm thickness using a diamond knife after trimming the blocks. The ultrathin section were placed on the formvar-coated Cu/Rh grids (Nissin EM Co., Ltd., Tokyo, Japan), stained with uranyl acetate and lead citrate, later observed under a transmission electron microscope (JEM-1200EX, Japanese Electric Co., Ltd.).

Results

Scanning electron microscopy

The images of UNICAL® diet in low calcium experiment rats (Fig. 1) were similar to that of

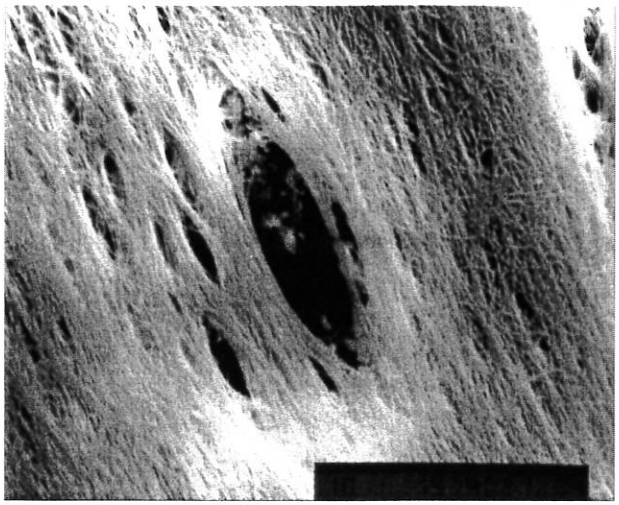

Fig. 5 SEM image of ossification area in UNICAL® diet experiment rats of the low calcium group. The bone matrix is dense. A large number of collagen fibrils pack closely to collagen fibrillar bundles. Bar: 10 μm

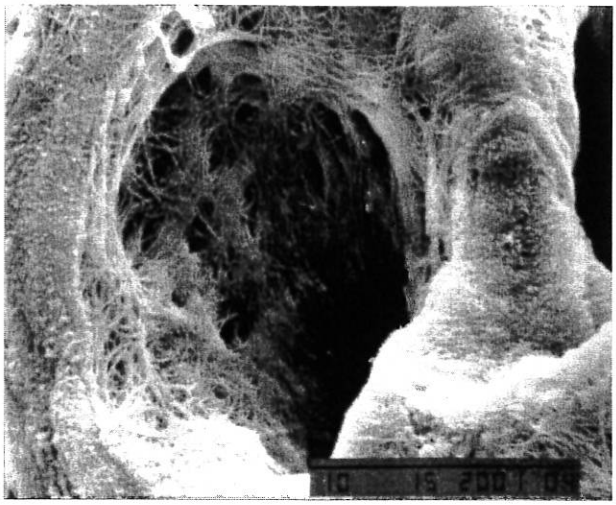

Fig. 6 SEM image of ossification area in pair-fed standard diet experiment rats of the low calcium group. The collagen fibrils are sparse. Some of them arrange to fibrillar bundles, and others cross to network in bone matrix. Bar: 10 μm

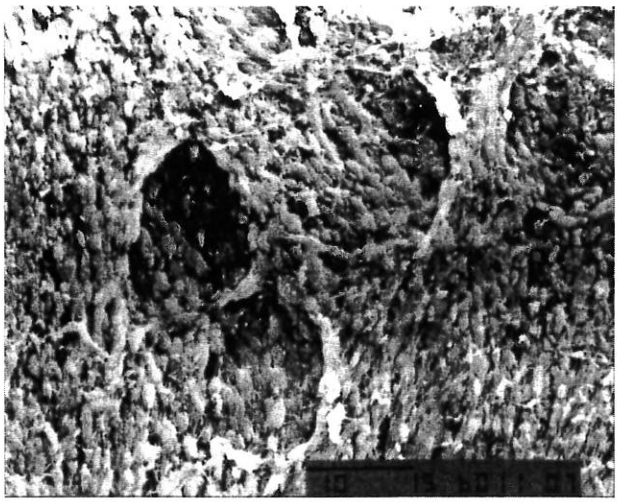

Fig. 7 SEM image of ossification area in UNICAL® diet experiment rats of the calcium deficient group. The outlines of osteocytes are irregular. The bone canaliculi are seldom opening their mouths to the wall of the osteocyte lacunae. The collagen fibrils consisting of bone matrix are slender, arrange irregularly, as well as the fibrillar bundles are thin. Bar: 10 μm

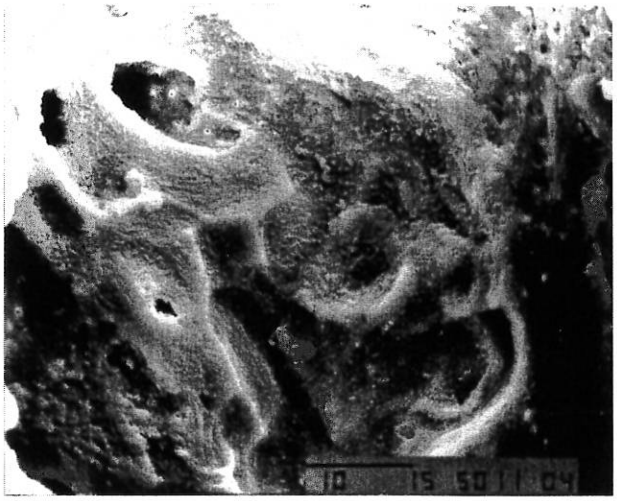

Fig. 8 SEM image of ossification area in UNICAL® diet experiment rats of the calcium deficient group. The bone resorption concaves show clear division with background of bone matrix. There are some osteocyte lacunae, at the wall of which bone canaliculi are opening their mouths, emergence in resorption foveas. Collagen fibrils cross into networks on upper surface of bone matrix. Bar: 10 μm

the control group rats in the mineralized hypertrophic cartilage along the ossification front. There were abundant calcospherites within a condrocytic lacuna, and the collagen fibers were found among the calcospherites. In the standard diet in low calcium experiment rats (Fig. 2), the interstitium among Condrocytic lacunae were wider, and the calcospherites sparser within a condrocytic lacuna than those in the control group rats and UNICAL® diet in the low calcium experiment rats. In UNICAL® diet experiment rats of the calcium deficient group, there was the distinct network of collagen fibers connecting these calcospherites with condrocytic lacuna (Fig. 3).

In the ossification areas, the more mature osteocytes with regular outline were easily observed in the control group rats (Fig. 4) and UNICAL® diet in the low calcium experiment rats (Fig. 5). There were a lot of bone canaliculi opened their mouths at the

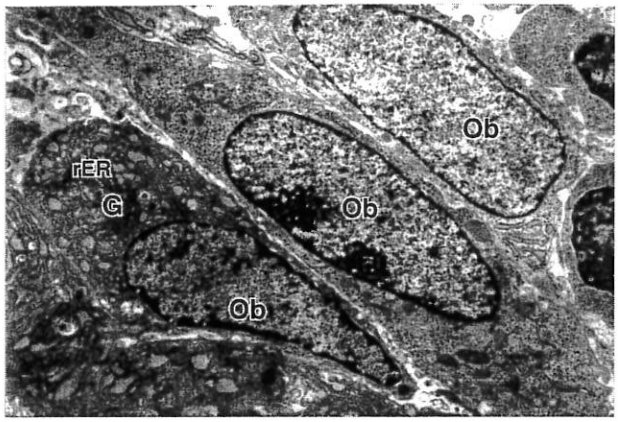

Fig. 9 TEM image of osteoblasts in the control group. There are three osteoblasts in the picture. The upper two fusiform cells, which have small cytoplasmic areas, poor-developed rough endoplasmic reticula, are relatively inactive osteoblasts. The other one, which is containing well-developed Golgi apparatus and rough endoplasmic reticula, is an active osteoblast. ×5,000

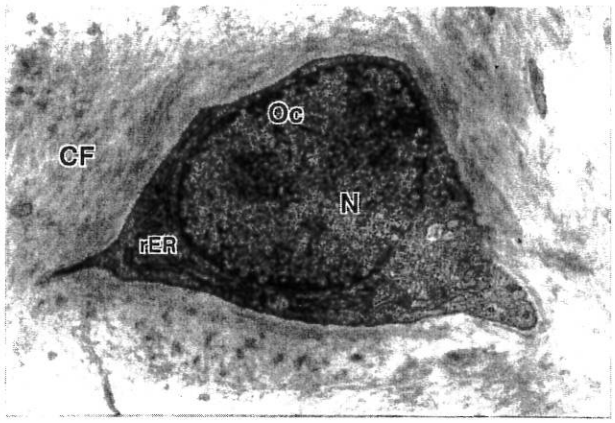

Fig. 10 TEM image of a mature osteocyte in the control group. The cell has a high ratio of nucleus to cytoplasmic with less organellar development, is embedded in bone matrix, and surrounded by regularly packed collagen fibrils. ×7,500

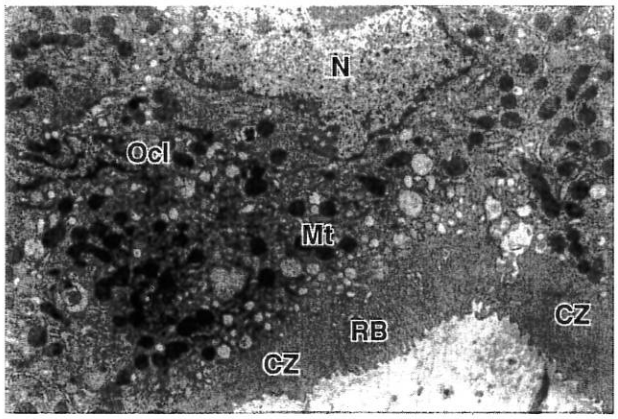

Fig. 11 TEM image of a part of an osteoclast in the control group. It Is showing the ruffled border and clear zone in resorption bone matrix. ×5,000

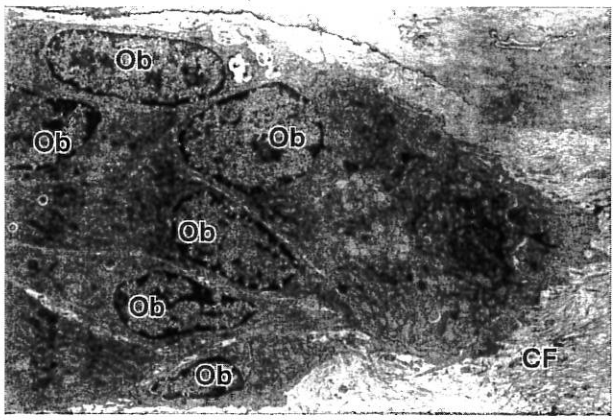

Fig. 12 TEM image of UNICAL® diet in the low calcium experiment rats. The collagen fibrils surrounding active osteoblasts, which contained well-developed Golgi apparatus and rough endoplasmic reticula, arrange irregularly. ×3,000

wall of the osteocyte lacunae. The bone matrix contained densely arranged collagen fibrils and a large number of closely packed collagen fibrillar bundles. The fibrillar bundles ran vertical and or oblique to the condylar surface. Comparison with UNICAL® diet rats, pair-fed standard diet experiment rats in the low calcium group were observed sparse collagen fibrils, which some arranged to fibrillar bundles, and others crossed to network in bone matrix (Fig. 6). In UNICAL® diet experiment rats of the calcium deficient group, the outlines of osteocytes were irregular. The bone canaliculi were seldom opening their mouths to the wall of the osteocyte lacunae. The collagen fibrils consisting of bone matrix were slender, arranged irregularly, as well as the fibrillar bundles were thin (Fig. 7). The bone resorption areas were indicated in the calcium deficient experiment group somewhere. The bone resorption concaves showed undulant outline and clear division with the background of bone matrix. There were some osteocyte lacunae, at the wall of which bone canaliculi were opening their mouths, emergence in resorption foveas. Collagen fibrils were seen crossed into networks on the upper surface of bone matrix (Fig. 8).

Transmission electron microscopy

In the control group, most of osteoblasts were not found in very active condition. Few active osteoblasts contained well-developed Golgi apparatus and rough endoplasmic reticula, the others relatively



Fig. 13 TEM image of UNICAL® diet in the low calcium experiment rats. It is showing the gap junction between osteocyte and osteoblast. ×4,000

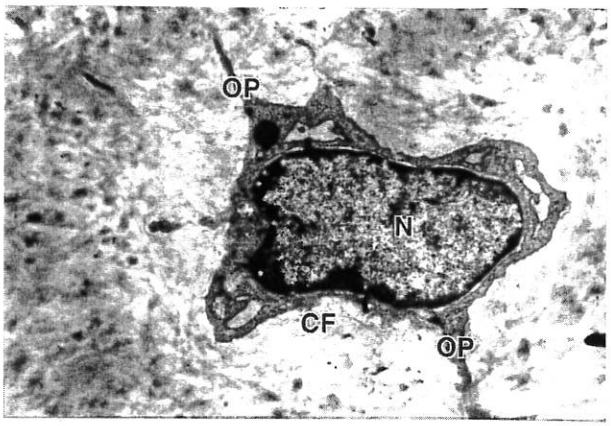

Fig. 14 TEM image of UNICAL® diet in the low calcium experiment rats. A mature osteocyte, which has a high nucleus to cytoplasmic ratio with less organellar development, is embedded in bone matrix. Some processes of the osteocyte are thin and buried into bone matrix. ×7,500

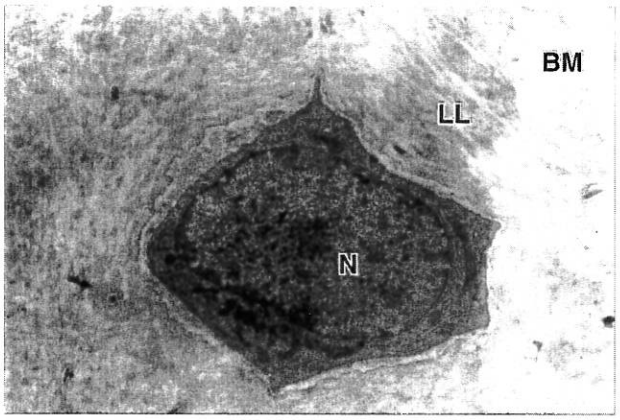

Fig. 15 TEM image of an osteocyte of UNICAL® diet in the low calcium experiment rats. The lamina limitans are surrounding osteocyte, and inside of the lamina limitans is unmineralized bone matrix, and outside of the lamina limitans is mineralized bone matrix. ×6,000

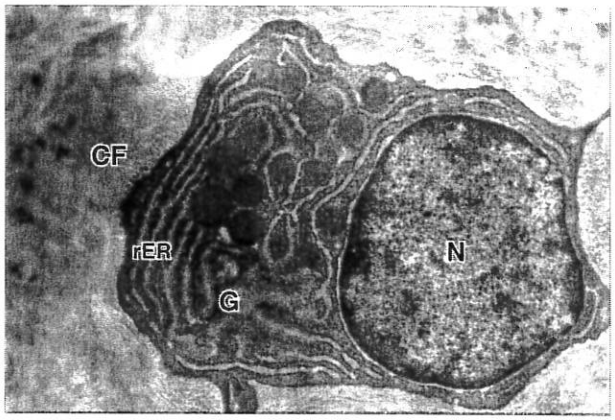

Fig. 16 TEM image of pair-fed standard diet in the low calcium experiment rats. A 'young' osteocyte is seen, which has some well-developed Golgi apparatus and rough endoplasmic reticula, lower ratio of nucleus to cytoplasm than that in mature osteocyte (Fig. 15). ×10,000

inactive osteoblasts elongated fusiformly revealed small cytoplasmic areas and poor-developed rough endoplasmic reticula (Fig. 9). The mature osteocytes in the control group, which had a high ratio of nucleus to cytoplasmic with less organellar development, were quite often observable. Generally, the cells were embedded in the bone matrix, and surrounded by regularly packed collagen fibrils (Fig. 10). The lamina limitans were observed surrounding osteocyte somewhere, inside of the lamina limitans was unmineralized bone matrix, outside of the lamina limitans was mineralized bone matrix. The osteoclasts were uncommonly found, which were large multinucleated cells and had numerous mitochondria and lysosomes. The portion of the cell contacting directly with bone matrix divided into two parts. One region containing numerous plasma membrane infoldings forming microvillous type structure was called ruffled border; the other lesser ring-like perimeter of cytoplasm called clear zone (Fig. 11).

The images of UNICAL® diet in the low calcium experiment rats were similar to that of the control group rats. The collagen fibrils surrounding active osteoblasts, which contained well-developed Golgi apparatus and rough endoplasmic reticula, arranged irregularly (Fig. 12). The gap junction between two osteocytes or between osteocyte and osteoblast

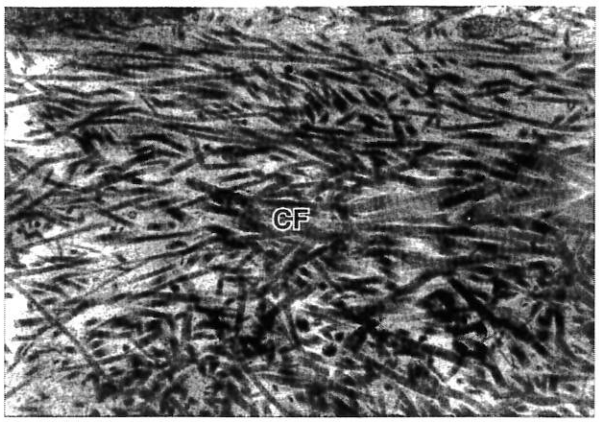

Fig. 17 TEM image of pair-fed standard diet in the low calcium experiment rats. The collagen fibrils surrounding 'young' osteocyte are irregular. ×20,000

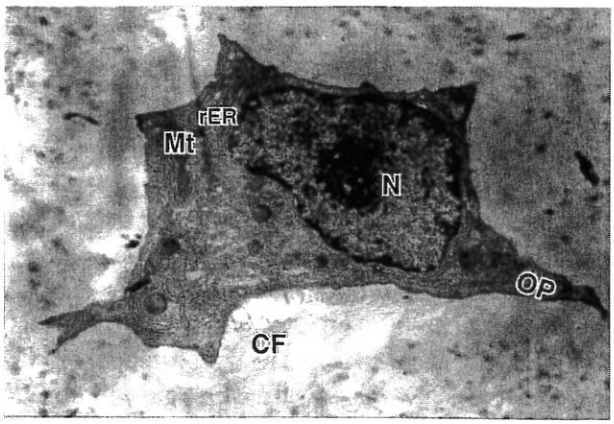

Fig. 18 TEM image of UNICAL® diet in the calcium deficient experiment rats. An osteocyte, which is containing well-developed rough endoplasmic reticula and mitochondria, reveals multi-processes. ×6,000

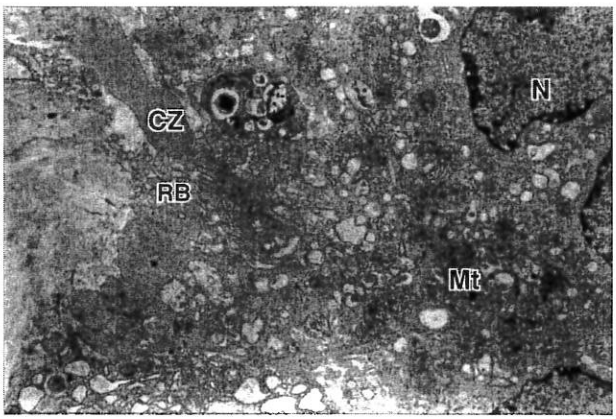

Fig. 19 TEM image of a part of an active osteoclast of UNICAL® diet in the calcium deficient experiment rats. There are numerous mitochondria, and clear functional ruffled border in the osteoclast. ×5,000

Abbreviations:

BM = bone matrix	CF = collagen fibrils
CZ = clear zone	GJ = gap junction
G = Goligi apparatus	Ob = osteoblast
Oc = osteocyte	Ocl = osteoclast
OP = osteocyte process	rER = rough endoplasmic reticulum
LL = lamina limitans	Mt = mitochondrion
N = nucleus	RB = ruffled border

(Fig. 13) were often observed. The mature osteocytes were embedded in the bone matrix (Fig. 14). The lamina limitans was observed surrounding osteocyte somewhere, and inside of the lamina limitans was unmineralized bone matrix, and outside of the lamina limitans was mineralized bone matrix. (Fig. 15).

In the pair-fed standard diet experiment rats of the low calcium group, the 'young' osteocytes were commonly seen, which had some well-developed Golgi apparatus and rough endoplasmic reticula, lower ratio of nucleus to cytoplasmic than that in mature osteocytes (Fig. 16). The collagen fibrils surrounding 'young' osteocytes were irregular (Fig. 17).

The osteocytes in UNICAL® diet experiment rats of the calcium deficient group varied in outline. The osteocytes revealed multi-processes (Fig. 18) commonly. The 'young' osteocytes, which had some well-developed Golgi apparatus and rough endoplasmic reticula, as well as the mature osteocytes, which had a high ratio of nucleus to cytoplasmic with less organellar development, were observable. The active osteoclasts, which had numerous mitochondria and lysosomes, and clear functional ruffled border (Fig. 19), were seemly often seen in comparison with that in other groups.

Discussion

The treatment of osteoporosis to prevent fracture is improving with newly introduced medications and approaches, but it is not as effective as needed. The effective prevention strategies are critical to de-

crease the morbidity and mortality of the disease. Peak bone mass, obtained during childhood and adolescent growth, is one of the major determinants for the risk of developing osteoporosis and fracture. Genetic potential, gender, ethnic origins, nutritional factors such as calcium and vitamin D_3 intake, growth patterns, and physical activity influence the accretion of bone mineral during childhood and determine the peak bone mass[5]. Calcium supplements are becoming an important source of dietary calcium, and a basic method against osteopenia[12–14]. Recent studies have also focused on a cancer preventive role for calcium[15–17]. Oral calcium supplement is very popular method for fortifying inadequate dietary calcium because its cheap cost, convenient intake way and minimal incidence of side effects[12,13] though a controversy still exists as to its effect on preventing age-related decrease of bone mass[18–19]. Now there are more than a dozen commonly prescribed calcium supplements and hundreds of different formulations commercially available[20–23]. Calcium carbonate is the major constituent in sea urchin shell and hydroxyapatite calcium, and is a preferred source of calcium supplements because of its high density of elemental calcium, about 40% by weight. Calcium citrate is another very popular formulation and there are now effervescent preparations available. At 21% by weight, the citrate preparations have a lower calcium content but are considered much more soluble than calcium carbonate, especially important in achlorhydric patients. The citrate ion may help to modulate the propensity for the development of renal stones[20]. The calcium citrate combined with IAM made from sea shell, is sort of oral calcium supplements.

The observation of scanning electron microscope is helpful to understand morphologic alteration on the bone surface during bone remodeling process. Sissons and his colleagues[24,25] found that bone resorption resulting from inadequate calcium diet was not accompanied by osteocytic resorption when osteocyte lacunae were observed under scanning electron microscope, and reported also that osteocyte lacunae in bone formed during the period of calcium deprivation were larger than those in comparable types of bone in the control rats under light microscopy. In the present study, we caution the phenomenon: the bone formation level of UNICAL® diet rats in the low calcium experiment group has been seemly improved upward to the level in the control group either in the mineralized hypertrophic cartilage along the ossification front or in ossification areas. It suggests that the mixture of calcium carbonate and calcium citrate has accelerated action on bone remodeling in the bone debilitation animals. Meanwhile, by comparison with the control group and the low calcium experiment group, the distinct bone resorption appearance is noted in the calcium deficient experiment group. The similar phenomenon was reported in previous studies[26–28]. It has been destined that mineralized cartilage served as a backbone for new bone formation as marrow-derived osteoblasts and osteoclasts attach to remnants of mineralized cartilage, which enables turning on the remodeling cycles involved in new bone formation. The calcospherites, most of that are associated with collagen fibrils, are evident that the Ca:P ratio is 2.1:1 using an X-ray dispersion analysis system. The ratio is close to that of hydroxyapatite[29]. The fibrillar network, which is a foundation of the condylar cartilage, seems to increase in fibril density with aging[30]. In the present investigation of scanning electron microscopy, the calcospherites in the mineralized hypertrophic cartilage of calcium deficient experiment group are less than that in the control group and UNICAL® diet rats in the low calcium experiment group within a condrocytic lacuna. Meanwhile, the network of collagen fibrils shows connecting the calcospherites with condrocytic lacuna. It suggests that the latent capacity of bone formation in the calcium deficient experiment group be reduced. The reduction is thought to have an inhibitory affection on the mandibular growth because a role of the condylar cartilage is an endochondral ossification center for mandibular growth, and the development of this zone takes place in the manner of appositional growth.

Generally, calcium supplement is recognized accelerating bone formation, and less inhibiting bone resorption[20]. It is demonstrated in the present investigation as the TEM observation described that the active osteoclasts, which have numerous mitochondria and lysosomes, and clear functional ruffled border, are seemly easily seen in UNICAL® diet experiment rats of the calcium deficient group. This recommends that the bone resorption process still being in an active condition though the experiment rats have been added calcium supplement as long as they were fed calcium deficient diet. Meanwhile, the active bone resorption phenomenon is noted in SEM observation also.

On the other hand, collagen fibrils surrounding active osteoblasts serve as a background of adding new bone matrix[31]. The collagen fibrils surrounding active osteoblasts is found irregular in UNICAL® diet experiment rats of the low calcium group though the other images of TEM observation as well as SEM observation are similar in the two groups. We consider the phenomenon that there is a subtle difference between UNICAL® diet in the low calcium experiment rats and control group rats. But it is not sure whether the difference would be expressed in mature bone matrix, for instance in bone mass.

Inadequate dietary calcium during the critical growth and building period may result in failure to reach peak bone mass, causing osteopenia, osteoporosis, decreased skeletal integrity, and increased risk of fracture in the later life[32,33]. The importance of ample calcium intake in early life is made evident by recent clinical studies[34–36], and experimental studies[37]. In the present study, the experimental range is from weanling period to early adulthood of rats. That is thought to be in critical period for peak bone mass gaining. We have got satisfactory result of bone ultrastructural alterations with UNICAL® diet in the low calcium experimental rats, but the result is not completely satisfactory in the calcium deficient experimental rats. The results suggest that the mixture of calcium carbonate and calcium citrate has a relatively positive effect on the bone debilitation to a certain extent but it has not been observed to help complete recovery of a serious bone debilitation caused by extremely inadequate dietary calcium in growth period. In addition, the performance prompted that recovery of serious bone debilitation is not easy. It might take longer time of giving calcium supplement, and also it is thought questionable for complete recovery, particularly only using oral calcium supplements.

References

1) Chesnut, C.H. 3d.: Is osteoporosis a pediatric disease? Peak bone mass attainment in the adolescent female. *Public Health Rep* **104** Suppl: 50–54, 1989.
2) Slemenda, C.W., Christian, J.C., Williams, C.L., Norton, L.A. and Johnston, Jr. C.C.: Genetic determinants of bone mass in adult women: a reevaluation of the twin model and the potential importance of gene interaction on heritability estimates. *J Bone Min Res* **6**: 561–567, 1991.
3) Johnston, Jr. C.C. and Slemenda, C.W.: Maximizing peak bone mass. *In:* Christiansen, C. and Riis, B. (eds): Osteoporosis proceedings. Alborg and Denmark, 1993, pp. 46–47.
4) Miller, G.D., Groziak, S.M. and DiRienzo, D.: Age consideration in nutrient needs for bone health. *J Am Coll Nutr* **15**: 553–555, 1996.
5) Stallings, V.A.: Calcium and bone health in children: a review. *Am J Ther* **4**: 259–273, 1997.
6) Recker, R.R., Davies, K.M., Hinders, S.M., Heaney, R.P., Stegman, M.R. and Kimmel, D.B.: Bone gain in young adult women. *JAMA* **268**: 2403–2408, 1992.
7) Okutomi, T.: Histopathological studies of periapical pathosis in rats with experimental osteoporosis. *Japan J Conserv Dent* **40**: 539–559, 1997. (in Japanese)
8) Nakano, Y.: Morphometric studies on influences of experimental osteoporosis in bone turnover at periapical lesion. *Japan J Conserv Dent* **40**: 560–576, 1997. (in Japanese)
9) Wactawski-Wende, L., Grossi, S.G., Trevisan, M., Genco, R.J., Tezal, M., Dunford, R.G., Ho, A.W., Hausmann, E. and Hreshchyshyn, M.M.: The role of osteopenia in oral bone loss and periodontal disease. *J Periodontol* **67** (10 suppl): 1076–1084, 1996.
10) Krall, E.A., Garcia, R.I. and Dawson-Hughes, B.: Increased risk of tooth loss is related to bone loss at the whole body, hip, and spine. *Calcif Tissue Int* **59**: 433–437, 1996.
11) Mori, H., Manabe, M., Kurachi, Y. and Nagumo, M.: Osseointegration of dental implants in rabbit bone with low mineral density. *J Oral Maxillofac Surg* **55**: 351–362, 1997.
12) Recker, R.R.: Prevention of osteoporosis: calcium nutrition. *Osteoporosis Int* **1** (suppl): 163–165, 1993.
13) Fujita, T.: Clinical Guidelines for the treatment of osteoporosis in Japan. *Calif Tissue Int* **59** (suppl): 34–37, 1996.
14) Raisz, L.R.: The osteoporosis revolution. *Ann Intern Med* **126**: 458–462, 1997.
15) Garland, G.F., Garland, F.C. and Corham, E.D.: Can colon cancer incidence and death rates be reduced with calcium and vitamin D. *Am J Clin Nutr* **54** (suppl): 193–201, 1991.
16) Martinez, M.E., Giovannucci, E.L., Colditz, G.A., Stampfer, M.J., Hunter, D.J., Speizer, F.E., Wing, A. and Willett, W.C.: Calcium, vitamin D, and the occurrence of colorectal cancer among women. *J Natl Cancer Inst* **88**: 1375–1382, 1996.
17) Keamey, L., Giovannucci, E., Rimm, E.B., Ascherio, A., Stampfier, M.L., Colditz, G.A., Wing, A., Kampman, E. and Willett, W.C.: Calcium, vitamin D, and dairy foods and the occurrence of colon cancer in men. *Am J Epidemiol* **143**: 907–917, 1996.
18) Riggs, B.L., Wahner, H.W., Melton, L.J. 3d, Richelson, L.S., Judd, H.L. and O'Fallon, W.M.: Dietary calcium intake and rates of bone loss in women. *J Clin Invest* **80**: 979–982, 1987.
19) Dawson, H.B., Jacques, P. and Shipp, C.: Dietary calcium intake and bone loss from the spine in healthy postmenopausal women. *Am J Clin Nutr* **46**: 685–687, 1987.

20) Levenson, D.I. and Bockman, R.S.: A review of calcium preparations. *Nutr Rev* **52**: 221–232, 1994.
21) Mason, N.A., Patel, J.D., Dressman, J.B. and Shimp, L.A.: Consumer vinegar test for determining calcium disintegration. *Am J Hosp Pharm* **49**: 2218–2222, 1992.
22) Charles, P.: Calcium absorption and calcium bioavailability. *J Intern Med* **231**: 161–168, 1992.
23) Shangraw, R.F.: Factors to consider in the selection of a calcium supplement. *Public Health Rep* **104**: 46–50, 1989.
24) Sissons, H.A., Kelman, G.J., Ling, L., Marotti, D., Cane, V. and Muglia, M.A.: A light and scanning electron microscopic study of osteocyte activity in calcium-deficient rats. *Calcif Tissue Int* **46**: 33–37, 1990.
25) Sisson, H.A., Kelman, G.J. and Marotti, G.: Mechanisms of bone resorption in calcium-deficient rats. *Calcif Tissue Int* **36**: 711–721, 1984.
26) Qirt, M., Zhang, Z.Y., Maki, K., Naito, M., Morimoto, M. and Kimura, M.: The effect of calcium supplement given with a mixture of calcium carbonate and calcium citrate on the mandibular alveolar bone of pubertal rats. *J Bone Miner Metab* **16**: 88–95, 1998.
27) Kimura, M., Nishida, I., Maki, K., Kaku, A., Yanome, S., Takahashi, H. and Matsuda, Y.: An experimental study of the effect of food on osteoporosis—especially on the mandible—. *Jpn J Ped Dent* **28**: 949–955, 1990. (in Japanese)
28) Kimura, K.: Radiological bone mass and histopathological study on diet therapy for bone debility in the rat at the growth stage. *J Kyushu Dent Soc* **51**: 42–72, 1997. (in Japanese)
29) Ben-Ami, Y., Lewinson, D. and Silbermann, M.: Structural characterization of the mandibular condyle in human fetuses: light and electron microscopy studies. *Acta Anat* **145**: 79–87, 1992.
30) Segawa, K. and Takiguchi, R.: Ultrastructural alteration of cartilaginous fibril arrangement in the rat mandibular condyle as revealed by high-resolution scanning electron microscopy. *Acta Rec* **234**: 493–499, 1992.
31) Marchi, E., Luder, H.U. and Leblond, C.P.: Changes in cells' secretory organells and extracellular matrix during endochondral ossification in mandibular condyle of the growing rat. *Am J Anat* **190**: 41–73, 1991.
32) Marchigiano, G.: Osteoporosis: primary prevention and intervention strategies for women at risk. *Home Care Provid* **2**: 76–81, 1997.
33) Tato, L., Antoniazzi, F. and Zamboni, G.: Bone mass formation in childhood and risk of osteoporosis. *Pediatr Med Chir* **18**: 373–375, 1996.
34) Matkovic, V., Jelic, T., Warddlaw, G.M., Ilich, J.Z., Goel, P.K., Wrigh, J.K., Andon, M.B., Smith, K.T. and Heaney, R.P.: Timing of peak bone mass in Caucasian females and its implication for the prevention of osteoporosis. *J Clin Invest* **93**: 799–808, 1994.
35) Chan, G.M.: Dietary calcium and bone mineral status of children and adolescents. *AJDC* **145**: 631–634, 1991.
36) Nowson, C.A., Green, R.M., Hopper, J.L., Sherwin, A.L., Young, D., Kaymakci, B., Guest, C.S., Smid, M., Larkins, R.G. and Wark, J.D.: A co-twin study of the effect of calcium supplementation on bone density during adolescence. *Osteoporos Int* **7**: 219–225, 1997.
37) Fujita, T., Fukase, M., Miyamoto, H., Matsumoto, T. and Ohue, T.: Increase of bone density by calcium supplement with oyster shell electrolysate. *Bone and Mineral* **11**: 85–91, 1990.